

Original article:

HESPERIDIN, A PLANT FLAVONOID ACCELERATED THE CUTANEOUS WOUND HEALING IN STREPTOZOTOCIN-INDUCED DIABETIC RATS: ROLE OF TGF-B/SMADS AND ANG-1/TIE-2 SIGNALING PATHWAYS

Wenbin Li¹, Amit D. Kandhare^{2,3*}, Anwasha A. Mukherjee², Subhash L. Bodhankar²

¹ Department of Dermatology, Shaanxi Traditional Chinese Medicine Hospital, Xi'an, Shaanxi, 710003, China

² Department of Pharmacology, Poona College of Pharmacy, Bharati Vidyapeeth Deemed University, Erandwane, Paud Road, Pune-411 038, India

³ Jalan Universiti Bandar Barat, 31900, Kampar, Perak, Malaysia

* Corresponding author: Dr. Amit D. Kandhare, Department of Pharmacology, Poona College of Pharmacy, Bharati Vidyapeeth Deemed University, Erandwane, Paud Road, Pune-411 038, India, E-mail: amitkandhare25@gmail.com

<http://dx.doi.org/10.17179/excli2018-1036>

This is an Open Access article distributed under the terms of the Creative Commons Attribution License (<http://creativecommons.org/licenses/by/4.0/>).

ABSTRACT

Background: Delayed wound healing is a diverse, multifactorial, complex and inter-related complication of diabetes resulting in significant clinical morbidity. Hesperidin possesses potent antidiabetic and wound healing activity.

Aim: To evaluate the potential of hesperidin against experimentally induced diabetes foot ulcers.

Methods: Diabetes was induced experimentally by streptozotocin (STZ, 55 mg/kg, i.p.) in Sprague Dawley rats (180-220 g) and wounds were created on the dorsal surface of the hind paw of rats. Hesperidin (25, 50 and 100 mg/kg, p.o.) was administered for 21 days after wound stabilization. Various biochemical, molecular and histopathological parameters were evaluated in wound tissue.

Results: STZ-induced decrease in body weight and increase in blood glucose, food, and water intake was significantly ($p < 0.05$) inhibited by hesperidin (50 and 100 mg/kg) treatment. It showed a significant increase ($p < 0.05$) in percent wound closure and serum insulin level. The STZ-induced decrease in SOD and GSH level, as well as elevated MDA and NO levels, were significantly ($p < 0.05$) attenuated by hesperidin (50 and 100 mg/kg) treatment. Intraperitoneal administration of STZ caused significant down-regulation in VEGF-c, Ang-1, Tie-2, TGF- β and Smad 2/3 mRNA expression in wound tissues whereas hesperidin (50 and 100 mg/kg) treatment showed significant up-regulation in these mRNA expressions. STZ-induced alteration in wound architecture was also attenuated by hesperidin (50 and 100 mg/kg) treatment.

Conclusion: Together, treatment with hesperidin accelerate angiogenesis and vasculogenesis via up-regulation of VEGF-c, Ang-1/Tie-2, TGF- β and Smad-2/3 mRNA expression to enhance wound healing in chronic diabetic foot ulcers.

Keywords: diabetic foot ulcer, hesperidin, VEGF-c, Ang-1, Tie-2, TGF- β , Smad 2/3

Abbreviations: Angiopoietin-1 (Ang-1), Diabetes mellitus (DM), Diabetic wound control (DWC), Hematoxylin and Eosin (H&E), Lipid peroxidation (MDA), Nitric oxide (NO), Normal non-diabetic (ND), Normal wound control (NWC), Reactive oxygen species (ROS), Reduced glutathione (GSH), Reverse Transcriptase Polymerase Chain Reaction (RT-PCR), Standard Error of Mean (SEM), Streptozotocin (STZ), Superoxide dismutase (SOD), Transforming growth factor- β (TGF- β), Tumor necrosis factor- α (TNF- α), Vascular endothelial growth factor (VEGF-c)

INTRODUCTION

Diabetes mellitus is a complex metabolic disorder affecting 171 million people worldwide, and this number is projected to reach 366 million by 2030 (Adil et al., 2017a, d; World Health Organization, 2016). Improper control of diabetes mellitus leads to an array of macro- and microvascular complications such as cardiomyopathy, encephalopathy, neuropathy, nephropathy, retinopathy and foot ulcer (Badole et al., 2015; Ghule et al., 2015; Nathan, 1993; Visnagri et al., 2014). Diabetic neuropathy is the main risk factor associated with a diabetic foot ulcer, and this ulcer is a serious problem in clinical practice (Kandhare et al., 2012c; Rafehi et al., 2011). It has been reported that amongst the diabetic patients 15 % will develop foot ulceration and wounds moreover 3 % of them will need amputation of a lower limb (Al-Watban et al., 2007).

Normal wound healing is a well-orchestrated process characterized by four distinct inter-related phases including hemostasis, inflammation, proliferation, and remodeling (Diegelmann and Evans, 2004; Patil et al., 2011). Coordination between various cells, local release of growth factors and cytokines influence the rate of wound repair whereas disruption in this cycle leads to delayed wound healing (Goswami et al., 2016; Shukla et al., 1997). Diabetes mellitus is well known, and major contributors to delayed or impaired wound healing resulted in chronic ulcer formation. Several lines of studies suggested peripheral neuropathy and microvascular diseases are the vital factors that are delayed wound healing in diabetic condition (Ghosh et al., 2012; Mustoe, 2004; Shivakumar et al., 2014).

Delayed wound healing exists with unknown etiology, and its underlying mechanisms are not yet completely understood. However, elevated oxidative stress, delayed collagen synthesis, decreased angiogenesis, impaired epithelialization and glucose metabolism, fibroblast and endothelial cell dysfunction has been reported as a vital pathophysiological factor in delaying the

wound-healing process (Adil et al., 2017b, d; Bajpai et al., 2009; Vijay et al., 2009). Furthermore, increased apoptosis signaling and abnormal expression of some gap junction proteins, i.e., connexins also delayed the wound-healing process (Clark, 2008). Numerous scientific reviews and studies demonstrate that inhibited production of transforming growth factor- β , insulin-like growth factor-1 and vascular endothelial growth factor resulted in delayed wound healing in diabetes mellitus (Perez Gutierrez and Vargas, 2006; Teoh et al., 2009).

In spite of tremendous advances in the pharmaceutical drug industry, the treatments for diabetic wound ulcer have not progressed substantially in recent years. Nowadays, the approved therapeutic implication for the treatment of diabetic foot ulcers are growth factor and cell therapies. However, their high cost and unwanted side effects limit their utility in the management of chronic wounds (Barrientos et al., 2014; Kandhare et al., 2017a). Furthermore, as diabetic foot ulcer is a complex and multi-event clinical problem hence, it cannot be treated by single means, and there is a need of co-adjuvant therapies such as antidiabetic and antibiotics for glycaemic and infection control. Moreover, it also needed daily wound care such as antiseptic bath as well as debridement and toe removal for gangrene depending upon need. Hence, there is an urge to the pursuit of new therapeutic agents for the treatment of non-healing diabetic foot ulcers.

An array of compounds derived from natural plants (such as triterpenes, alkaloids, flavonoids) receives increasing acceptance (Kandhare et al., 2016b; Paocharoen, 2010) due to non-toxic nature as well as they have an ability to influence one or more wound healing phases (Panchatcharam et al., 2006; Sumitra et al., 2005). In the light of the experimental evidence, it is documented that novel herbal moieties contain numerous phytoconstituents that can be explored to the management of chronic wounds. A large number of the popularly used ayurvedic plants have not been scientifically examined

for their efficacy and anti-diabetic properties (Patel et al., 2012). Furthermore, literature has indicated that animal models of impaired healing may have greater clinical relevance (Kandhare et al., 2014; Nunan et al., 2014) and played a vital role in the scientific evaluation of these unexplored moieties from the herbal origin. Since delayed diabetic wound healing is composite of multiple factors including impaired glycemic control, peripheral neuropathy, and lowered immunity against infections hence, Streptozotocin (STZ)-induced diabetic wound is an ideal model that represents these clinicopathological features of diabetic foot ulcer (Kandhare et al., 2011).

Hesperidin (hesperetin-7-rhamnoglucoside) is a major plant flavonoid abundantly present in a variety of citrus species including *Citrus aurantium L.*, *C. sinensis*, *C. unshiu* (Rutaceae) (Emim et al., 1994; Kawaguchi et al., 1997). Studies have shown hesperidin have many biological functions, including anti-diabetic, antihyperlipidemic, anti-ulcers, anti-inflammatory, anti-microbial, analgesic, antifungal, hepatoprotective, antioxidant, antiallergic, anti-cancer, anti-hypertensive and anti-atherogenic potential (Akiyama et al., 2010; Jin et al., 2008; Kandhare et al., 2017b; Kaur et al., 2006; Kawaguchi et al., 1997; Lee et al., 2004; Nandakumar et al., 2011; Shah and Patel, 2010; Shi et al., 2012). There is a report indicating that hesperidin ameliorates sodium arsenite-induced toxicity in rats (Pires Das Neves et al., 2004).

Recently, the wound healing potential of hesperidin has been proven in experimental animal models and clinical trials (Ahmad et al., 2013; Godeberge, 1994; Hasanoglu et al., 2001; Struckmann and Nicolaidis, 1994). The role of hesperidin in diabetes-induced complication such as diabetic nephropathy, neuropathy, cardiomyopathy, and encephalopathy have been proven effectively (Ibrahim, 2008; Shah and Patel, 2010). To best of our knowledge, no study has been carried out that evaluated the effect of hesperidin in the diabetic wound. Hence, the aim of present in-

vestigation to evaluate the potential of administration of hesperidin against experimentally induced diabetes foot ulcers.

MATERIAL AND METHOD

Animals

Adult Sprague Dawley rats (male, 180-220 g) were obtained from the National Institute of Biosciences, Pune (India). Rats were housed at 24 ± 1 °C, with a relative humidity of 45–55 % and 12:12 h dark/light cycle. The animals had free access to standard pellet chow (Pranav Agro Industries Ltd., Sangli, India) and filtered water throughout the experimental protocol. All experiments were carried out between 09:00 and 17:00 h. The experiment was conducted according to the guidelines of Committee for Control and Supervision of Experimentation on Animals (CPCSEA), Government of India on animal experimentation.

Chemicals

Hesperidin and Streptozotocin (Sigma Chemical Co., St Louis, MO, USA), Total RNA Extraction kit (MP Biomedicals India Private Limited, India) and One-step Reverse transcription-polymerase chain reaction (RT-PCR) kit (MP Biomedicals India Private Limited, India), GOD - POD (glucose oxidase-peroxidase) diagnostic kit (Accurex Biomedical Pvt. Ltd., Mumbai, India) were procured from respective manufacturer.

Induction and assessment of diabetes

Diabetes was induced by intraperitoneal administration of streptozotocin (STZ, 55 mg/kg) in citrate buffer (pH 4.4, 0.1 M) (Visnagri et al., 2012). A separate group of age-matched control rats were also maintained which received an equal volume of citrate buffer. Retro-orbital plexus technique was used to collect the blood samples, and GOD-POD was used to estimate serum glucose levels. Rats having serum glucose levels more than 250 mg/dL were selected as diabetic and used for the present study.

Excision wound model

Excision diabetic foot ulcer was created according to the previously established method (Kandhare et al., 2014). Briefly, on the day of wound creation, each rat was anesthetized with ketamine (75 mg/kg, i.p.) and xylazine (10 mg/kg, i.p.). The rectangular wound (2 mm × 5 mm) was created on the dorsal surface of the foot of each rat. The rats were randomly divided into various experimental groups.

Experimental design

After wound creation, rats were divided into following experimental groups (n=6, each):

A. Non-diabetic and non-wounded animals

Group I: Normal non-diabetic (ND): non-diabetic animals without wound received double distilled water (10 mg/kg, p.o.) for 21 days.

B. Non-diabetic and wounded animals

Group II: Normal wound control (NWC): non-diabetic animals with wound received a single injection of citrate buffer (vehicle), and then double distilled water (10 mg/kg, p.o.) for 21 days.

C. Diabetic and wounded animals

Group III: Diabetic wound control (DWC): diabetic animals with wound received double distilled water (10 mg/kg, p.o.) for 21 days.

Group IV: Hesperidin (H (25)): diabetic animals with wound received hesperidin (25 mg/kg, p.o.) for 21 days.

Group V: Hesperidin (H (50)): diabetic animals with wound received hesperidin (50 mg/kg, p.o.) for 21 days.

Group VI: Hesperidin (H (100)): diabetic animals with wound received hesperidin (100 mg/kg, p.o.) for 21 days.

Group VII: Insulin (I (10)): diabetic animals with wound received insulin (10 IU/kg, s.c.) for 21 days.

Every day the three different dosages of hesperidin, i.e., 25, 50 and 100 mg/kg were freshly and administered to animals for 21 days. On various days, the wound area was determined with the help of digital camera

(Fuji, S20 Pro, Japan) by an observer blind to the treatment. The metabolic cages (Techniplast, Italy) were used to determine food intake and water intake.

After 22 days, rats were anesthetized under etheral anesthesia and blood was withdrawn by a retro-orbital puncture for determination of serum parameters. Then, animals were sacrificed by cervical dislocation and wound tissues were rapidly removed and stored at -80 °C for biochemical parameters.

Measurement of the wound area, calculation of wound contraction and determination of half-closure time (CT50)

On day various days including 4, 8, 12, 16 and 21, the progressive changes in wound area were recorded using camera (Fuji, S20 Pro, Japan). Then, the wound area was determined using image analysis software (Image J, NIH, USA).

The percent (%) wound closure was calculated by following formula: % Wound closure = $100 * [(Initial\ wound\ area) - (N^{th}\ day\ wound\ area) / (Initial\ wound\ area)]$.

The graph of percent wound closure versus time in days from wound creation was plotted using the software GraphPad Prism v5.0, and linear regression analysis was performed. The value of X corresponds to Y=50 % was consider as CT50 (half-closure time, the time taken to close the wound by 50 %).

Determination of serum insulin

The serum was separated by centrifugation (4 °C, 5200 g, 15 min) using Eppendorf Cryocentrifuge (model No. 5810, Germany). The assay of serum insulin was performed by a rat ELISA (enzyme-linked immunosorbent assay) kit (Mercodia AB, Uppsala, Sweden).

Biochemical estimations

Preparation of tissue homogenate

Skin tissue segments were weight and mixed with 0.1 M phosphate buffer (pH 7.4) and homogenized on ice for 60 seconds at 10600 g (Remi Equipment Pvt. Ltd., Remi

Motors Ltd., Mumbai, India). Supernatant of tissue homogenates was used to determine superoxide dismutase (SOD), reduced glutathione (GSH), lipid peroxidation (MDA), nitric oxide (NO), and hydroxyproline content as described previously (Adil et al., 2016b; Honmore et al., 2015; Kandhare et al., 2012a,b, 2013, 2015d; Mohod et al., 2016; Mukherjee et al., 2015).

Reverse transcriptase PCR analysis of VEGF-c, Ang-1, Tie-2, TGF-β and Smad 2/3 mRNA expression

The reverse transcription (RT)-PCR used to determine mRNA levels in skin tissue (Adil et al., 2016a; Kandhare et al., 2013, 2015c; Mohod et al., 2016). Briefly, total RNA was extracted from skin tissues according to the manufacturer's instructions (MP Biomedicals India Private Limited, India). The polymerase chain reaction mixture was amplified in a DNA thermal cycler (Eppendorf India Ltd, Chennai, India) by using gene-specific primers (Table 1). PCR products were run on 1 % agarose gel, stained with ethidium bromide. Gene expression was assessed by generating densitometry data for band intensities in different sets of experiments, by analyzing the gel images on the Image J program (Version 1.33, Wayne Rasband, National Institutes of Health, Bethesda, MD, USA). The

band intensities were compared with constitutively expressed β-actin which served as a control for sample loading and integrity. The intensity of mRNAs was standardized against that of the β-actin mRNA from each sample, and the results were expressed as PCR-product/β-actin mRNA ratio.

Histopathological examination

Another portion of skin tissue was stored in 10 % formalin for 24 h. The specimen was dehydrated and placed in xylene for 1 h (3 times) and later in ethyl alcohol (70, 90 and 100 %) for 2 h respectively. The infiltration and impregnation were carried out by treating with paraffin wax twice, each time for 1 h. Tissue specimens were cut into sections of 3-5 μm thickness and were stained with hematoxylin and eosin (H&E). The specimen was mounted on the slide by use of DPX (distrene, with dibutyl phthalate and xylene) as mounting medium. Sections were examined under a light microscope to obtain a general impression of the histopathology features of specimen and infiltration of cells. The various changes in histological features were graded as Grade 0 (not present); Grade 1 (mild); Grade 2 (moderate); and Grade 3 (severe) as described previously (Patil et al., 2012c).

Table 1: Primer sequences for VEGF-c, Ang-1, Tie-2, TGF-β, Smad 2/3, and β-actin

Sr. No.	Gene	Sequence		Size (bp)
		Forward primer	Reverse primer	
1	VEGF-c	CCCTGATGAGATCGAG-TACATCTT	ACCGCCTCGGCTTGTCAC	210
2	Ang-1	GCTGGCAGTACAATGACAGT	GTATCTGGGCCATCTCCGAC	512
3	Tie-2	ATTGACGTGAAGATCAA-GAATGCCACC	ATCCGGATTGTTTTT-GGCCTTCTGTT	375
4	TGF-β	GTTCTTCAATACGTCAGACATTCG	CATTATCTTTGCTGTCAACAAGAGC	309
5	Smad-2/3	AGCACACAATAACTTGGACC	TAAGACACACTGGAACAGCG-GATG	368
6	β-actin	GTCACCCACAC-TGTGCCCATCT	ACAGAGTACTTGCGCTCAGGAG	764

Statistical analysis

Data are expressed as mean \pm standard error mean (SEM). Data analysis was performed using Graph Pad Prism 5.0 software (Graph Pad, San Diego, CA, USA). Data of wound area and percentage wound closure were analyzed using two-way repeated analysis of variance (ANOVA), and Bonferroni's multiple range test was applied for post hoc analysis, while data of biochemical parameters were analyzed using one-way analysis of variance (ANOVA), and Tukey's multiple range test was applied for post hoc analysis. A value of $p < 0.05$ was considered to be statistically significant.

RESULTS

Effect of hesperidin and insulin treatment on body weight, serum glucose level and serum insulin of diabetic rats

There was a significant decrease ($p < 0.05$) in body weight and serum insulin level whereas an increase in serum glucose level of vehicle control rats after induction of diabetes by intraperitoneal administration of STZ. Treatment with hesperidin (50 and 100 mg/kg) significantly ($p < 0.05$) inhibit STZ-induced decrease in body weight and serum insulin level as compared to diabetic wound control. An elevated level of serum glucose level also significantly ($p < 0.05$) decreased by hesperidin (50 and 100 mg/kg) as compared to diabetic wound control (Table 2). Administration of insulin (10 IU/kg) also significant ($p < 0.05$) increased body weight and serum insulin level whereas significantly decreased ($p < 0.05$) serum glucose level as compared to diabetic wound control. Insulin (10 IU/kg) also showed more significant decrease ($p < 0.05$) in serum glucose level and significant increase ($p < 0.05$) in serum insulin level as compared to hesperidin (25, 50 and 100 mg/kg) treatment (Table 2).

Effect of hesperidin and insulin treatment on food and water intake of diabetic rats

The food and water intake were increased significantly ($p < 0.05$) in diabetic wound

control rats after intraperitoneal administration of STZ. Treatment with hesperidin (50 and 100 mg/kg) significantly ($p < 0.05$) reduced the food and water intake when compared with diabetic wound control rats. Diabetes-induced increase in food and water intake was also significantly ($p < 0.05$) reduced by insulin treatment (10 IU/kg) when compared with diabetic wound control rats. Insulin (10 IU/kg) treatment showed more significant ($p < 0.05$) improvement to the altered food and water intake as compared to hesperidin (25 and 50 mg/kg) treated rats (Table 2).

Effect of hesperidin and insulin treatment on rate of wound contraction and CT50 of diabetic rats

The effect of hesperidin and insulin treatment on the morphology of various stages of wound healing is shown in Figure 1. Diabetic wound control rats showed a higher wound area where the rate of wound contraction was lower over a period of 21 days. The wound area was significantly decreased ($p < 0.05$), and the rate of wound contraction was significantly ($p < 0.05$) increased by hesperidin (50 and 100 mg/kg) treatment when compared with diabetic wound control rats. The wound area and rate of wound contraction were also significantly ameliorated ($p < 0.05$) by treatment with insulin (10 IU/kg) as compared to diabetic wound control rats (Table 2). Furthermore, the rate of wound contraction was significantly higher ($p < 0.05$) in hesperidin (100 mg/kg) treated rats as compared to insulin (10 IU/kg) treated rats (Table 2).

The CT50 value for diabetic wound control rats was -272.6 days (negative sign indicated delayed wound healing). CT50 value for the combination of hesperidin (25, 50 and 100 mg/kg) treated rats was 67.95, 22.78 and 13.78 days respectively whereas, CT50 values for insulin (10 IU/kg) treated rats was 21.77 days (Table 2).

Table 2: Effect of hesperidin and insulin treatment on body weight, serum glucose level, food intake, water intake, serum insulin and CT50 of diabetic rats

Treatment	Body Weight (gm)	Serum Glucose Level (mg/dL)	Food Intake (gm)	Water Intake (ml)	Serum Insulin (mg/L)	% Wound Closure (at day 21)	CT50 (days)
Normal	195.83 ± 4.79	285.36 ± 9.50	46.55 ± 2.15	68.62 ± 4.22	2.68 ± 0.12	---	---
NWC	185.50 ± 4.04 ^{&}	288.38 ± 12.97	48.12 ± 4.45 ^{&}	64.62 ± 4.79 ^{&}	2.71 ± 0.33	29.45 ± 10.22	25.78
DWC	165.17 ± 2.37 [#]	331.38 ± 11.75 [#]	72.13 ± 2.56 [#]	120.45 ± 8.12 [#]	0.52 ± 0.21 [#]	-22.35 ± 8.44 [#]	-263.0
I (10)	200.17 ± 3.51 ^{*,§}	285.01 ± 16.34 ^{*,§}	35.22 ± 3.19 ^{*,§}	48.12 ± 4.11 ^{*,§}	2.59 ± 0.86 ^{*,§}	50.33 ± 11.22 ^{*,§}	19.77
H (25)	173.33 ± 2.01	319.28 ± 9.29	64.50 ± 3.12	112.63 ± 4.23	0.89 ± 0.21	15.55 ± 4.23	77.95
H (50)	192.67 ± 4.53 ^{*,§}	294.62 ± 15.24 ^{*,§}	52.12 ± 4.73 ^{*,§}	95.12 ± 2.01 ^{*,§}	1.56 ± 0.56 ^{*,§}	45.28 ± 12.33 ^{*,§}	68.78
H (100)	195.67 ± 2.99 ^{*,§}	289.18 ± 2.50	50.62 ± 3.47 ^{*,§}	88.70 ± 3.77 ^{*,§}	2.34 ± 0.98 ^{*,§}	96.77 ± 18.54 ^{*,§}	52.78

Data are expressed as mean ± SEM (n = 6) and analyzed by one-way ANOVA followed by Tukey's multiple range test for each parameter separately. [&]p < 0.05 as compared to normal, [#]p < 0.05 as compared to normal wound control, ^{*}p < 0.05 as compared to diabetic wound control group and [§]p < 0.05 as compared to one another. NWC: Normal wound control group; DWC: Diabetic wound control group; I (10): Insulin (10 IU/kg, s.c.) treated group; H (25): Hesperidin (25 mg/kg, p.o.) treated group; H (50): Hesperidin (50 mg/kg, p.o.) treated group; H (100): Hesperidin (100 mg/kg, p.o.) treated group; CT50: Time at which 50 % of the cutaneous wound was closed. The negative sign in CT50 value indicated delayed wound healing.

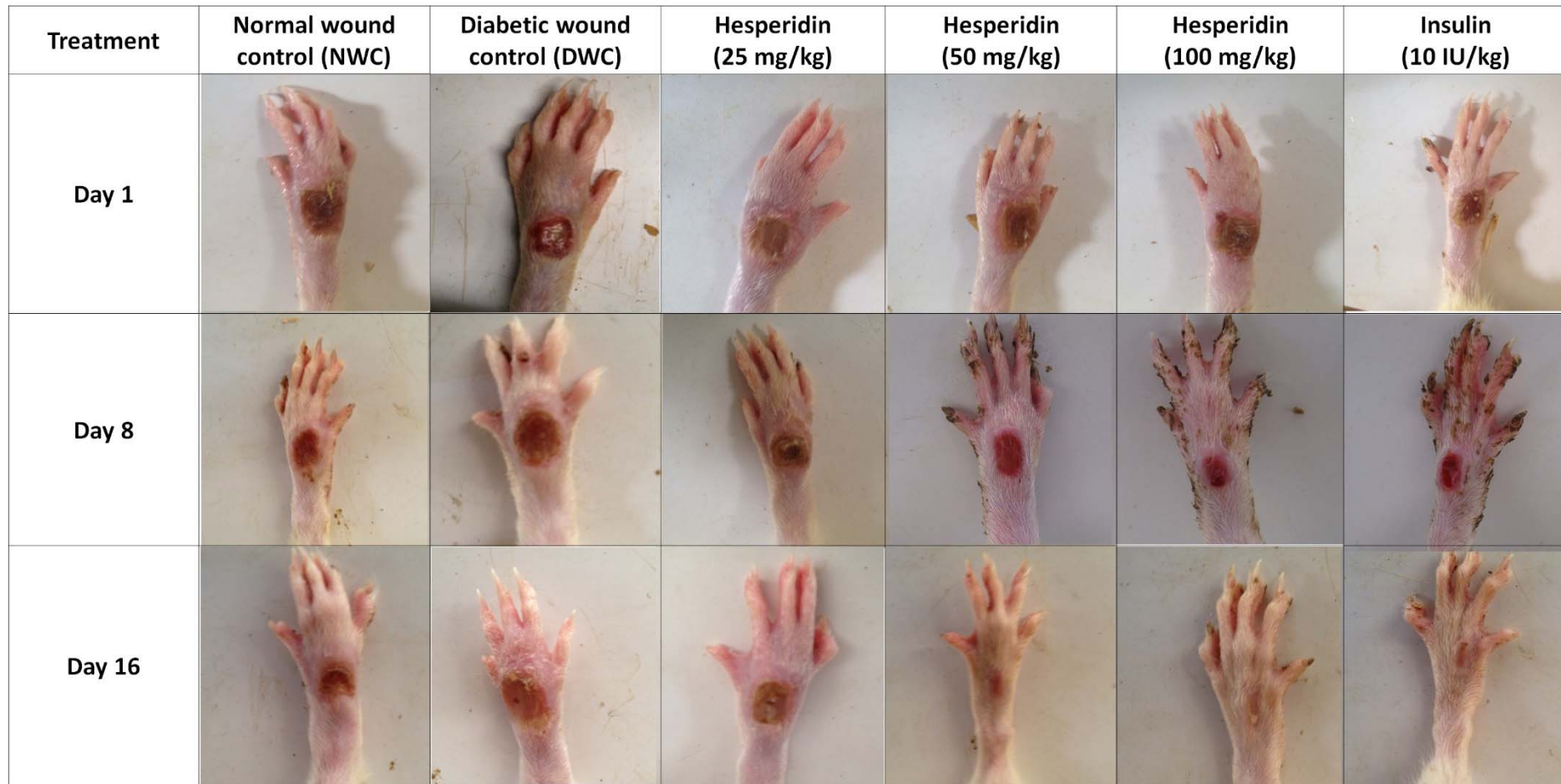


Figure 1: Morphological representation of rat paws showing various phases of wound healing

Effect of hesperidin and insulin treatment on the oxido-nitrosative stress of diabetic rats

The SOD and GSH levels decreased significantly ($p < 0.05$) and MDA and NO levels increased significantly ($p < 0.05$) in normal wound control rats and diabetic wound control rats. Treatment with hesperidin (50 and 100 mg/kg) significantly ($p < 0.05$) reduced diabetes-induced alterations in oxido-nitrosative stress when compared with diabetic wound control rats. Insulin treatment (10 IU/kg) also significantly ($p < 0.05$) inhibited diabetes-induced alteration in SOD, GSH, MDA and NO levels as compared to diabetic wound control rats (Table 3).

Effect of hesperidin and insulin treatment on hydroxyproline level of diabetic rats

Diabetic wound control rats showed significant ($p < 0.05$) decrease in hydroxyproline level as compared to normal wound control as well as normal control rats. When compared with diabetic wound control rats, hesperidin (50 and 100 mg/kg) treatment significantly ($p < 0.05$) increased hydroxyproline level. Hydroxyproline level also significantly ($p < 0.05$) increased by treatment with insulin (10 IU/kg) as compared with diabetic wound control rats. When compared with insulin (10 IU/kg) treatment, hesperidin (50 and 100 mg/kg) treated rats showed significantly higher ($p < 0.05$) hydroxyproline level (Table 3).

Effect of hesperidin and insulin treatment on VEGF-c, Ang-1, Tie-2, TGF- β and Smad 2/3 mRNA expression in wound skin tissue of diabetic rats

There was down-regulation in VEGF-c, Ang-1, Tie-2, TGF- β and Smad 2/3 mRNA expression in skin tissue of normal wound control rats as well as diabetic wound control rats. The mRNA expression of VEGF-c, Ang-1, Tie-2, TGF- β and Smad 2/3 were up-regulated significantly ($p < 0.05$) in hesperidin (50 and 100 mg/kg) treatment when compared to diabetic wound control rats. Insulin

(10 IU/kg) treatment also significantly inhibited ($p < 0.05$) STZ-induced down-regulation in VEGF-c, Ang-1, Tie-2, TGF- β and Smad 2/3 mRNA expression as compared to diabetic wound control rats. There was a significant ($p < 0.05$) up-regulation in VEGF-c, Tie-2, TGF- β and Smad 2/3 mRNA expression in the hesperidin (100 mg/kg) treated group as compared to insulin (10 IU/kg) treated rats (Figure 2).

Effect of hesperidin and insulin treatment on diabetes-induced histopathological alterations in skin tissue of diabetic rats

Figure 3A represented the normal architecture of normal tissue from normal control rats. It showed the presence of vessels, epithelial layer with few polymorphonuclear leukocyte infiltrations (red arrow, grade 1). Figure 3B showed the distorted architecture of skin from normal wound control rats. Wound tissue from diabetic control rats showed the presence of ectopic vessels with edema along with polymorphonuclear leukocyte infiltration (red arrow, grade 4). It also showed thicker epithelial layer and disorganized fibroblasts (Figure 3C). Skin tissue from insulin (10 IU/kg) treated rats showed well-organized dermal layers with decreased polymorphonuclear leukocyte infiltration (red arrow, grade 2) with re-epithelialization (yellow arrow, grade 3) and new vessels formation (black arrow, grade 3) (Figure 3D). Wound tissue from the hesperidin (25 mg/kg) treated rats demonstrated incomplete epithelialization (grade 1), lesser number new vessels (grade 1), and polymorphonuclear leukocyte infiltration (grade 3) (Figure 3E). Histopathology of wound skin from hesperidin (50 and 100 mg/kg) treated rats revealed an increased number of blood vessels (grade 3), re-epithelialization (grade 3) with mild polymorphonuclear leukocyte infiltration (grade 1) (Figure 3F and Figure 3G, respectively) (Table 4).

Table 3: Effect of hesperidin and insulin treatment on the oxido-nitrosative stress and hydroxyproline level of diabetic rats

Treatment	SOD (U/mg of protein)	GSH (μ g/mg of protein)	MDA (nM/mg of protein)	NO (μ g/mL)	Hydroxyproline (μ g/mg tissue)
Normal	8.67 \pm 0.49	6.27 \pm 0.74	6.14 \pm 0.7	14.76 \pm 2.29	4.42 \pm 0.44
NWC	4.12 \pm 0.75 ^{&}	2.52 \pm 0.18 ^{&}	15.26 \pm 0.74 ^{&}	34.4 \pm 3.92 ^{&}	1.5 \pm 0.19 ^{&}
DWC	2.22 \pm 0.38 [#]	1.99 \pm 0.2 [#]	21.06 \pm 0.64 [#]	58.05 \pm 2.66 [#]	0.99 \pm 0.16 [#]
I (10)	7.38 \pm 0.37 ^{*,§}	5.61 \pm 0.72 ^{*,§}	8.76 \pm 0.35 ^{*,§}	48.23 \pm 3.26 ^{*,§}	2.09 \pm 0.41 ^{*,§}
H (25)	3.74 \pm 0.44	2.21 \pm 0.17	19.63 \pm 0.94	51.7 \pm 4.78	1.05 \pm 0.14
H (50)	5.75 \pm 0.51 ^{*,§}	3.83 \pm 0.35 ^{*,§}	15.59 \pm 1.44 ^{*,§}	42.36 \pm 4.16 ^{*,§}	2.48 \pm 0.33 ^{*,§}
H (100)	6.39 \pm 0.53 ^{*,§}	4.99 \pm 0.41 ^{*,§}	11.3 \pm 1.1 ^{*,§}	33.34 \pm 2.98 ^{*,§}	3.12 \pm 0.48 ^{*,§}

Data are expressed as mean \pm SEM (n = 4) and analyzed by one-way ANOVA followed by Tukey's multiple range test for each parameter separately. [&]p < 0.05 as compared to normal, [#]p < 0.05 as compared to normal wound control, ^{*}p < 0.05 as compared to diabetic wound control group and [§]p < 0.05 as compared to one another. NWC: Normal wound control group; DWC: Diabetic wound control group; I (10): Insulin (10 IU/kg, s.c.) treated group; H (25): Hesperidin (25 mg/kg, p.o.) treated group; H (50): Hesperidin (50 mg/kg, p.o.) treated group; H (100): Hesperidin (100 mg/kg, p.o.) treated group; SOD: Superoxide Dismutase; GSH: Reduced Glutathione; MDA: Malondialdehyde; NO: Nitric Oxide.

Table 4: Effect of hesperidin and insulin treatment on wound healing processes and healing phases of diabetic rats

Treatment	Epithelization	Polymorphonuclear Leukocyte	Fibroblasts	New vessels
Normal	++++	+	++++	++++
NWC	+	+++	++	+
DWC	+	++++	+	-
I (10)	+++	++	++	+++
H (25)	+	+++	+	+
H (50)	++	++	+++	++
H (100)	++++	+	+++	+++

NWC: Normal wound control group; DWC: Diabetic wound control group; I (10): Insulin (10 IU/kg, s.c.) treated group; H (25): Hesperidin (25 mg/kg, p.o.) treated group; H (50): Hesperidin (50 mg/kg, p.o.) treated group; H (100): Hesperidin (100 mg/kg, p.o.) treated group.

Note: 0: no abnormality detected; +: damage/active changes up to less than 25 %; ++: damage/active changes up to less than 50 %; +++: damage/active changes up to less 75 %; ++++: damage/active changes up to more than 75 %

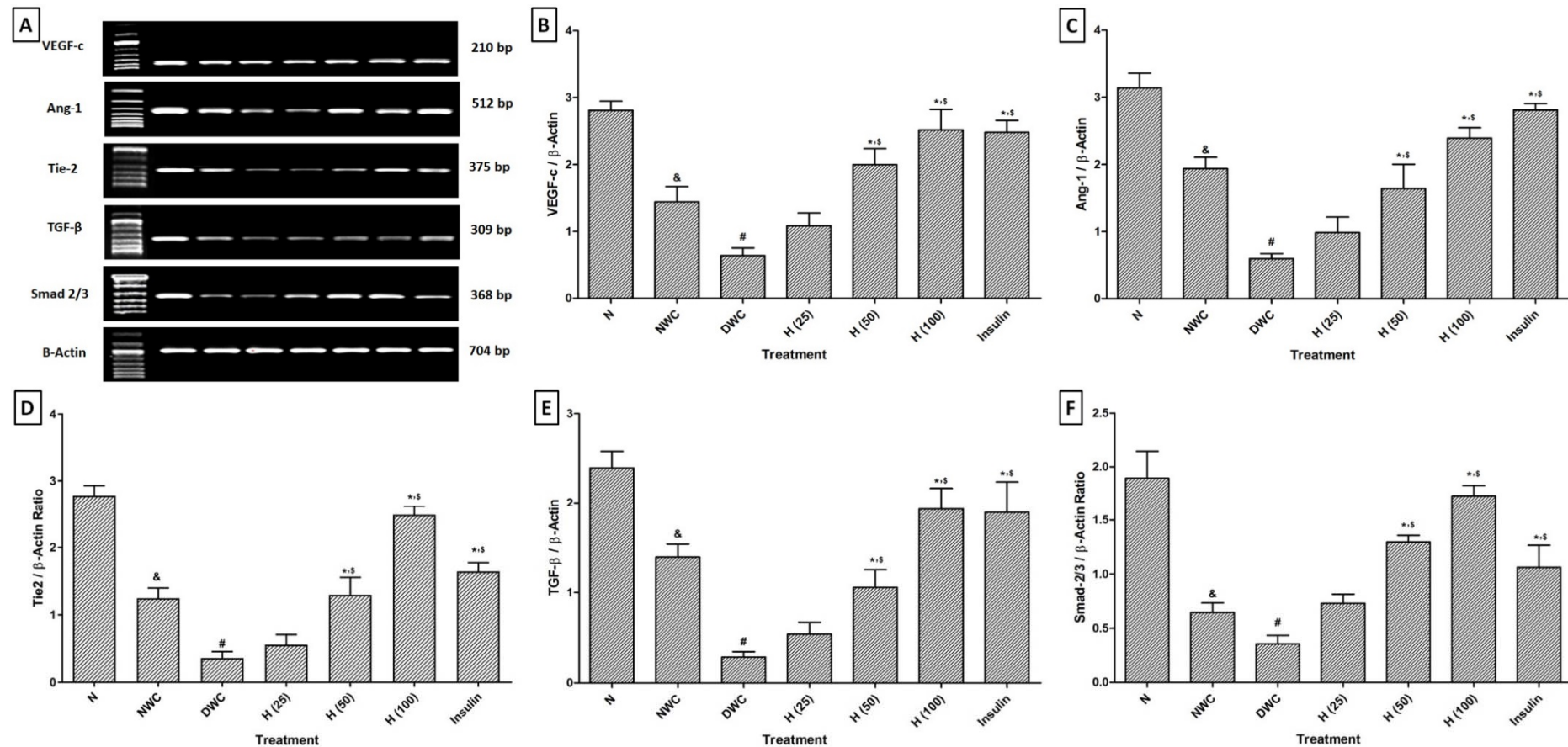


Figure 2: Effect of hesperidin and insulin treatment on mRNA expression of VEGF-c, Ang-1, Tie-2, TGF- β and Smad 2/3 in wound tissue as determined by relative quantification by reverse transcriptase polymerase chain reaction analysis (A), Quantitative representation of mRNA expression of VEGF-c, Ang-1, Tie-2, TGF- β and Smad 2/3 (B-F). Data are expressed as mean \pm SEM (n = 6) and analyzed by one-way ANOVA followed by Tukey's multiple range test for each parameter separately. [&]p < 0.05 as compared to normal, [#]p < 0.05 as compared to normal wound control, ^{*}p < 0.05 as compared to diabetic wound control group and [§]p < 0.05 as compared to one another. NWC: Normal wound control group; DWC: Diabetic wound control group; I (10): Insulin (10 IU/kg, s.c.) treated group; H (25): Hesperidin (25 mg/kg, p.o.) treated group; H (50): Hesperidin (50 mg/kg, p.o.) treated group; H (100): Hesperidin (100 mg/kg, p.o.) treated group.




Figure 3: Photomicrographs of sections of Hematoxylin & eosin-stained wound skin tissues. Microscopic image of wound skin of normal control rats (A), normal wound control rat (B), diabetic (STZ) wound control group (C), hesperidin (25 mg/kg, p.o.)-treated group (D), hesperidin (50 mg/kg, p.o.)-treated group (E), hesperidin (50 mg/kg, p.o.)-treated group (F) and insulin (10 IU/kg, s.c.)-treated group (G). Formation of new vessels (black arrow), the formation of epithelization (yellow arrow) and inflammatory infiltration (red arrow). Images ($\times 100$ magnification) are typical and representative of each study group.

DISCUSSION

Delayed wound healing is a diverse, multifactorial, complex and inter-related complication of diabetes resulting in significant clinical morbidity. Common causes of diabetic foot ulcer include elevated blood sugar that leads to impaired blood flow and oxygen release, protein malnutrition that causes decreased collagen and fibronectin synthesis, decreased local immune and cell defenses and impaired insulin and growth hormone (Adil et al., 2017c; Reiser, 1991). Moreover, it has been documented that hyperglycemia leads to dysfunctioning of neutrophil which includes migration, chemotaxis, adherence and phagocytic and bactericidal potential (Wall et al., 2003). Wound healing process includes a sequence of biological events including wound closure, repair, and remodeling of damaged tissue (Phillips et al., 1991). However, the presence of hyperglycemia causes delayed wound healing, and therefore it led to the development of many pharmacological treatments. The current treatment regimen is able to show the effect on only one of the underlying cause, and they are also associated with undesirable side effects (Suh et al., 1998). Hence, there is a need for safer and more effective healing agents which shows effect via acting through more than one mechanism in diabetic foot ulcer. In the view of this, we have investigated the effect of administration of hesperidin in STZ-induced diabetic foot ulcer by evaluating various biochemical and molecular parameters.

Researcher revealed that decrease body weight provided insight to disease state (Kamble et al., 2013; Tambewagh et al., 2017). In the present study, intraperitoneal administration of STZ caused a significant decrease in body weight, and this observation is similar to earlier reports (Kandhare et al., 2014, 2017a). In the past, researchers have underlined the correlation between diabetes and decrease in the availability of glucose and amino acid. The impaired cellular biosynthesis and metabolism are considered as an underlying cause of unavailability of glucose and amino acid which is induced by diabetes

(Adil et al., 2014, 2017a). In agreement with other literature, the finding of the present study showed that intraperitoneal administration of STZ resulted in features like polydipsia, and polyphagia (Kandhare et al., 2014) whereas administration of hesperidin significantly attenuated this diabetes-induced polydipsia, and polyphagia.

Studies have shown a predominant role for fibroblasts during wound healing process (Etscheid et al., 2004). Contraction of the wound is an essential phenomenon in healing process which mediated via fibroblasts within the granular tissue by differentiation of fibroblasts into myofibroblasts (Sidhu et al., 1999). This fibroblast proliferation leads to increased collagen production (Chen et al., 2005). The presence of myofibroblasts in the healing area is considered as an important feature of tissue undergoing contraction (Moulin et al., 2000). Researchers previously reported that hesperidin treatment enhances wound healing in non-diabetic rats (Ahmad et al., 2013; Godeberge, 1994; Hasanoglu et al., 2001; Struckmann and Nicolaidis, 1994). In the present investigation, administration of hesperidin showed enhanced wound healing which may be due to its potential for increased fibroblasts proliferation.

Angiogenesis plays a crucial role in homeostasis and development of organs (Heinke et al., 2012). Furthermore, in adults, the important integral feature of angiogenesis in wound healing, ischemic diseases recovery and tissue regeneration (Navaratna et al., 2009). Its dysregulation leads to the pathogenesis of an array of maladies including microvascular complications (neuropathy and retinopathy), cancer, and arthritis (Bhilare et al., 2016; Gosavi et al., 2011; Kandhare et al., 2016a; Patil et al., 2012a). The process of angiogenesis leads to the generation of new vessels from pre-existing ones that help to alleviate some states including healing of wounds through delivering oxygen and nutrients (Crivellato, 2011). Numerous scientific reviews and studies demonstrate that recent therapies caused stimulation of only one angiogenic factor (e.g., vascular endothelial

growth factor (VEGF-c)) (Navaratna et al., 2009). However, nowadays it is becoming a need that therapeutic moiety should be enhanced angiogenesis through modulation of various angiogenic factors and their receptors (Carmeliet and Jain, 2011; Chung and Ferrara, 2011). A compelling body of evidence supports that angiogenesis delayed by hyperglycemia (Bek et al., 2002; da Costa Pinto and Malucelli, 2002). Therefore, it is important to reduce hyperglycemia along with an increase in angiogenesis for the treatment of diabetic foot ulcer healing (Frykberg and Banks, 2015). Interestingly, in the present study, treatment with hesperidin significantly decreased blood sugar level and also increased angiogenesis. This possible interplay between wound contraction and hyperglycemia by hesperidin treatment may accelerate the diabetic wound healing process.

Although the precise mechanism of foot ulcer caused by diabetes is not clear, there is evidence that elevated blood sugar level can cause generation of reactive oxygen metabolites and inhibit the activity of antioxidant enzymes in tissue (Kandhare et al., 2012a, 2017a; Visnagri et al., 2014). Numerous literature have supported the direct link between oxidative stress and diabetic foot ulcer (Bajpai et al., 2009; Kandhare et al., 2014). Oxidative stress is generated via reactive oxygen species (ROS) that plays an important role in down-regulation of endogenous antioxidant enzymes such as SOD and GSH (Adil et al., 2014; Aswar et al., 2015; Kandhare et al., 2015a, b; Ketkar et al., 2015). Furthermore, these elevated levels of ROS also associated with elevated levels of lipid peroxidation (i.e., malonaldehyde or MDA) which destroyed membrane lipid bilayer arrangement (Mukherjee et al., 2017; Patil et al., 2012b; Raygude et al., 2012; Visnagri et al., 2013). These consequences caused an alteration in tissue permeability and deactivation of membrane-bound receptors. Additionally, excessive synthesis of NO plays a key role in oxidative damage via interacting with superoxide to generate the peroxynitrite (Kandhare et al., 2016c; Kumar et al., 2014;

Patil et al., 2012d). It has been suggested that antioxidants may play an important role in abating some hazards which are associated with elevated oxido-nitrosative stress (Devkar et al., 2016; Gosavi et al., 2012; Kandhare et al., 2017c). In the present investigation, hesperidin exerts an antioxidant effect through scavenging free radicals or via activating/inducing cellular antioxidant enzyme systems. Numerous evidence supported the antioxidant potential of hesperidin overproduction of free radicals in an array of disease which is associated with depletion of antioxidant enzymes such as SOD, GSH, MDA and NO (Kandhare et al., 2017b; Visnagri et al., 2014). Results of the present investigation are in accordance with the findings of the previous investigator.

Angiopoietin 1 (Ang-1), a type of 70 kDa glycoprotein from angiopoietin family, serves as a ligand of the Tie receptor tyrosine kinase (Pafumi et al., 2015). The phosphorylation of the Tie-1 receptor by Ang-1 initiates Ang-1-Tie signaling, and this Ang-1-Tie interaction resulted in its expression in endothelial cells where it plays a vital role in angiogenesis for development and regeneration (Dallabrida et al., 2005; Jeansson et al., 2011). Cho et al. (2005) reported the accelerated wound healing via angiogenesis by application of recombinant adenovirus encoding angiopoietin-1 (Ad-Ang-1). Thus, a moiety which has an ability to activate Ang-1-Tie signaling that serves as a promising therapeutic candidate for effective angiogenesis and vascular protection (Koh, 2013). In the present study, treatment with hesperidin caused up-regulation in Ang-1-Tie resulted in increased angiogenesis leading to accelerated wound healing via stabilized blood vessel integrity and vascular remodeling. Results of the present investigation are in line with the findings of the previous investigation which showed the angiogenic potential of hesperidin (Haddadi et al., 2017).

Vascular endothelial growth factor (VEGF-c) is a cytokine that is produced by numerous cell types such as keratinocytes, macrophages, and fibroblasts (Altavilla et al.,

2001). VEGF-c is responsible for endothelial cell survival, proliferation, and migration. It has been previously described that vasculogenesis also plays an important role in the healing process along with angiogenesis (Visconti et al., 2002). It is also reported that VEGF-c is an endogenous stimulator of angiogenesis (Corral et al., 1999). Furthermore, angiogenesis is associated with expression of cytokines and angiogenic factors which includes VEGF-c (Ferrara et al., 2003). So collectively, both angiogenesis and vasculogenesis can be accelerated by activation of VEGF-c and Ang-1 respectively. In diabetic condition, the VEGF-c level was decreased and resulted in increased activity of gap junction. This causes increased apoptotic, pro-inflammatory, and toxic signaling pathways from injured part to adjacent healthy parts through gap junctions which resulted in impaired wound healing process (Suarez and Ballmer-Hofer, 2001). In the light of this report, our results also showed delayed wound healing in diabetic animals. Whereas, treatment with hesperidin showed improvement in the altered healing process via enhancement in the impaired angiogenesis through Ang-1/VEGF-c dependent manner. The previous investigator also showed a significant increase in VEGF-c level in the rat skin tissue *in-vivo* after treatment with hesperidin (Haddadi et al., 2017). Results of the present investigation agreed with the findings of the previous researcher.

An array of evidence suggests that diabetes is associated with various connective tissue abnormalities. Collagen is an important extracellular connective tissue protein that provides strength and integrity to the tissue matrix (Raghow, 1994). Abnormalities in the synthesis of this connective tissue protein at the wound area after an injury delays healing process (Nwomeh et al., 1999). Hyperglycemia is one the factors that interfere with collagen synthesis. Thus, delays wound healing in diabetes (Goodson III and Hunt, 1977). Hydroxyproline is served as a hallmark of collagen turnover (Ricard-Blum and Ruggiero, 2005). It is well documented that collagen

synthesis can be accelerated by the process of angiogenesis which increases the delivery of oxygen and other nutrients at the site of local injury to elevate the local collagen turnover (Buemi et al., 2002). Furthermore, simultaneous stimulation of collagen and VEGF-c synthesis have also been reported beneficial during delayed wound healing (Kandhare et al., 2014). In congruence with the literature, our findings show that treatment with hesperidin caused increased angiogenesis, VEGF-c and collagen synthesis that may result in accelerated wound healing in diabetic foot ulcer.

It has already been known that Smad2 and Smad3 dissociate from the receptor complex and form another heteromeric complex with Smad4. These complexes translocate into the nucleus and trigger pro-fibrogenic genes that are amenable to TGF- β (Adil et al., 2015, 2016c). In the current study, intraperitoneal administration of STZ caused noteworthy down-regulation of TGF- β expression in wound tissues as compared to normal wound rats which are concurrent with the previous reports (Hozzein et al., 2015). For instances, the body of evidence showed that considerably increased TGF- β protein expression, and Smad-2/3 phosphorylation is positively linked to fibrosis through TGF- β /Smad pathway in diabetic foot ulcer (Xu et al., 2013). In the past, it has been reported that amplified TGF- β and Smad-2/3 expression for wound tissue is in accordance with elevated deposition of collagens (Xu et al., 2013). Taken our current data together with evidence from other groups, it can be concluded that diabetic induced foot ulcer is strongly allied with decreased TGF- β and Smad-2/3 mRNA expression. However, administration of hesperidin significantly upregulates TGF- β and Smad-2/3 mRNA expression in wound tissue. The result of the present investigation is in accordance with the findings of the previous researcher (Wu et al., 2015).

Recently, flavonoids have been reported efficacious and cost-effective in the management of chronic foot ulcers (Antunes-Ricardo et al., 2015). Furthermore, two herbal

formulae were shown its wound healing potential against chronic diabetic ulcers in a randomized, double-blind, placebo-controlled trial (Leung et al., 2008). These remarkable a series of scientific evidence may open novel vistas for the therapeutic option of diabetic foot ulcers with natural remedies like hesperidin. In conclusion, results of present investigations showed that hesperidin treatment inhibited diabetes-induced increased blood glucose level and down-regulated VEGF-c, Ang-1/Tie-2, TGF- β and Smad-2/3 mRNA expression to accelerate angiogenesis and vasculogenesis resulted in enhances wound healing in chronic diabetic foot ulcers.

Conflict of interest

The authors declare no conflict of interest.

REFERENCES

- Adil M, Visnagri A, Kumar VS, Kandhare AD, Ghosh P, Bodhankar S. Protective effect of naringin on sodium arsenite induced testicular toxicity via modulation of biochemical perturbations in experimental rats. *Pharmacologia*. 2014;5:222-34.
- Adil M, Kandhare AD, Visnagri A, Bodhankar SL. Naringin ameliorates sodium arsenite-induced renal and hepatic toxicity in rats: decisive role of KIM-1, Caspase-3, TGF-beta, and TNF-alpha. *Ren Fail*. 2015; 37:1396-407.
- Adil M, Kandhare AD, Dalvi G, Ghosh P, Venkata S, Raygude KS, et al. Ameliorative effect of berberine against gentamicin-induced nephrotoxicity in rats via attenuation of oxidative stress, inflammation, apoptosis and mitochondrial dysfunction. *Ren Fail*. 2016a;38: 996-1006.
- Adil M, Kandhare AD, Ghosh P, Venkata S, Raygude KS, Bodhankar SL. Ameliorative effect of naringin in acetaminophen-induced hepatic and renal toxicity in laboratory rats: role of FXR and KIM-1. *Ren Fail*. 2016b;38:1007-20.
- Adil M, Kandhare AD, Ghosh P, Bodhankar SL. Sodium arsenite-induced myocardial bruise in rats: Ameliorative effect of naringin via TGF- β /Smad and Nrf/HO pathways. *Chem Biol Interact*. 2016c;253:66-77.
- Adil M, Ghosh P, Venkata SK, Raygude K, Gaba D, Kandhare AD, et al. Effect of anti-diabetic drugs on risk of fracture in type 2 diabetes mellitus patients: a network meta-analytic synthesis of randomized controlled trials of thiazolidinediones. *Value Health*. 2017a;20(9):A526.
- Adil M, Khan RA, Kalam A, Venkata SK, Kandhare AD, Ghosh P, et al. Effect of anti-diabetic drugs on bone metabolism: Evidence from preclinical and clinical studies. *Pharmacol Rep*. 2017b;69:1328-40.
- Adil M, Mansoori MN, Singh D, Kandhare AD, Sharma M. Pioglitazone-induced bone loss in diabetic rats and its amelioration by berberine: A portrait of molecular crosstalk. *Biomed Pharmacother*. 2017c;94: 1010-9.
- Adil M, Khan RA, Ghosh P, Venkata SK, Kandhare AD, Sharma M. Pioglitazone and risk of bladder cancer in type 2 diabetes mellitus patients: A systematic literature review and meta-analysis of observational studies using real-world data. *Clin Epidemiol Global Health*. 2017d, epub ahead of print. <https://doi.org/10.1016/j.cegh.2017.08.002>
- Ahmad M, Ansari MN, Alam A, Khan TH. Oral dose of citrus peel extracts promotes wound repair in diabetic rats. *Pak J Biol Sci*. 2013;16:1086-94.
- Akiyama S, Katsumata S, Suzuki K, Ishimi Y, Wu J, Uehara M. Dietary hesperidin exerts hypoglycemic and hypolipidemic effects in streptozotocin-induced marginal type 1 diabetic rats. *J Clin Biochem Nutr*. 2010; 46(1):87-92.
- Al-Watban FA, Zhang XY, Andres BL. Low-level laser therapy enhances wound healing in diabetic rats: a comparison of different lasers. *Photomed Laser Surg*. 2007;25(2):72-7.
- Altavilla D, Saitta A, Cucinotta D, Galeano M, Deodato B, Colonna M, et al. Inhibition of lipid peroxidation restores impaired vascular endothelial growth factor expression and stimulates wound healing and angiogenesis in the genetically diabetic mouse. *Diabetes*. 2001;50:667-74.
- Antunes-Ricardo M, Gutierrez-Urbe J, Serna-Saldivar SO. Anti-inflammatory glycosylated flavonoids as therapeutic agents for treatment of diabetes-impaired wounds. *Curr Top Med Chem*. 2015;15:2456-63.
- Aswar UM, Kandhare AD, Mohan V, Thakurdesai PA. Anti-allergic effect of intranasal administration of type-A procyanidin polyphenols based standardized extract of cinnamon bark in ovalbumin sensitized BALB/c mice. *Phytother Res*. 2015;29:423-33.

- Badole SL, Chaudhari SM, Jangam GB, Kandhare AD, Bodhankar SL. Cardioprotective Activity of Pongamia pinnata in Streptozotocin-Nicotinamide Induced Diabetic Rats. *Biomed Res Int.* 2015;2015:403291.
- Bajpai S, Shukla VK, Tripathi K, Srikrishna S, Singh RK. Targeting connexin 43 in diabetic wound healing: future perspectives. *J Postgrad Med.* 2009;55:143-9.
- Barrientos S, Brem H, Stojadinovic O, Tomic-Canic M. Clinical application of growth factors and cytokines in wound healing. *Wound Repair Regen.* 2014;22:569-78.
- Bek EL, McMillen MA, Scott P, Angus LD, Shaftan GW. The effect of diabetes on endothelin, interleukin-8 and vascular endothelial growth factor-mediated angiogenesis in rats. *Clin Sci (Lond).* 2002;103(Suppl 48):424S-9S.
- Bhilare NV, Dhaneshwar SS, Sinha AJ, Kandhare AD, Bodhankar SL. Novel thioester prodrug of N-acetylcysteine for odor masking and bioavailability enhancement. *Curr Drug Deliv.* 2016;13:611-20.
- Buemi M, Vaccaro M, Sturiale A, Galeano MR, Sansotta C, Cavallari V, et al. Recombinant human erythropoietin influences revascularization and healing in a rat model of random ischaemic flaps. *Acta Derm Venereol.* 2002;82:411-7.
- Carmeliet P, Jain RK. Molecular mechanisms and clinical applications of angiogenesis. *Nature.* 2011;473(7347):298-307.
- Chen J, Kasper M, Heck T, Nakagawa K, Humpert PM, Bai L, et al. Tissue factor as a link between wounding and tissue repair. *Diabetes.* 2005;54:2143-54.
- Cho CH, Kim KE, Byun J, Jang HS, Kim DK, Baluk P, et al. Long-term and sustained COMP-Ang1 induces long-lasting vascular enlargement and enhanced blood flow. *Circ Res.* 2005;97:86-94.
- Chung AS, Ferrara N. Developmental and pathological angiogenesis. *Annu Rev Cell Dev Biol.* 2011;27:563-84.
- Clark RA. Oxidative stress and "senescent" fibroblasts in non-healing wounds as potential therapeutic targets. *J Invest Dermatol.* 2008;128:2361-4.
- Corral CJ, Siddiqui A, Wu L, Farrell CL, Lyons D, Mustoe TA. Vascular endothelial growth factor is more important than basic fibroblastic growth factor during ischemic wound healing. *Arch Surg.* 1999;134:200-5.
- Crivellato E. The role of angiogenic growth factors in organogenesis. *Int J Dev Biol.* 2011;55:365-75.
- da Costa Pinto FA, Malucelli BE. Inflammatory infiltrate, VEGF and FGF-2 contents during corneal angiogenesis in STZ-diabetic rats. *Angiogenesis.* 2002;5:67-74.
- Dallabrida SM, Ismail N, Oberle JR, Himes BE, Rupnick MA. Angiopoietin-1 promotes cardiac and skeletal myocyte survival through integrins. *Circ Res.* 2005;96(4):e8-24.
- Devkar ST, Kandhare AD, Zanwar AA, Jagtap SD, Katyare SS, Bodhankar SL, et al. Hepatoprotective effect of withanolide-rich fraction in acetaminophen-intoxicated rat: decisive role of TNF- α , IL-1 β , COX-II and iNOS. *Pharm Biol.* 2016;54:2394-403.
- Diegelmann RF, Evans MC. Wound healing: an overview of acute, fibrotic and delayed healing. *Front Biosci.* 2004;9:283-9.
- Emim JA, Oliveira AB, Lapa AJ. Pharmacological evaluation of the anti-inflammatory activity of a citrus bioflavonoid, hesperidin, and the isoflavonoids, dauricin and claussequinone, in rats and mice. *J Pharm Pharmacol.* 1994;46:118-22.
- Etscheid M, Beer N, Kress JA, Seitz R, Dodt J. Inhibition of bFGF/EGF-dependent endothelial cell proliferation by the hyaluronan-binding protease from human plasma. *Eur J Cell Biol.* 2004;82:597-604.
- Ferrara N, Gerber HP, LeCouter J. The biology of VEGF and its receptors. *Nat Med.* 2003;9:669-76.
- Frykberg RG, Banks J. Challenges in the treatment of chronic wounds. *Adv Wound Care (New Rochelle).* 2015;4:560-82.
- Ghosh P, Kandhare AD, Raygude KS, Kumar VS, Rajmane AR, Adil M, et al. Determination of the long term diabetes related complications and cardiovascular events using UKPDS risk engine and UKPDS outcomes model in a representative western Indian population. *Asian Pac J Trop Dis.* 2012;2:S642-S50.
- Ghule AE, Kandhare AD, Jadhav SS, Zanwar AA, Bodhankar SL. Omega-3-fatty acid adds to the protective effect of flax lignan concentrate in pressure overload-induced myocardial hypertrophy in rats via modulation of oxidative stress and apoptosis. *Int Immunopharmacol.* 2015;28:751-63.
- Godeberge P. Daflon 500 mg in the treatment of hemorrhoidal disease: a demonstrated efficacy in comparison with placebo. *Angiology.* 1994;45:574-8.
- Goodson III WH, Hunt TK. Studies of wound healing in experimental diabetes mellitus. *J Surg Res.* 1977;22:221-7.

- Gosavi T, Kandhare A, Raygude K, Ghosh P, Bodhankar S. Evaluation of clinical outcome in arthritis with AIMS2. *Deccan J Pharmacol.* 2011;2(3):10-30.
- Gosavi TP, Ghosh P, Kandhare AD, Kumar VS, Adil M, Rajmane AR, et al. Therapeutic effect of *H. pylori* nosode, a homeopathic preparation in healing of chronic *H. pylori* infected ulcers in laboratory animals. *Asian Pac J Trop Dis.* 2012;2:S603-S11.
- Goswami S, Kandhare A, Zanwar AA, Hegde MV, Bodhankar SL, Shinde S, et al. Oral L-glutamine administration attenuated cutaneous wound healing in Wistar rats. *Int Wound J.* 2016;13:116-24.
- Haddadi G, Abbaszadeh A, Mosleh-Shirazi MA, Okhovat MA, Salajeghe A, Ghorbani Z. Evaluation of the effect of hesperidin on vascular endothelial growth factor gene expression in rat skin animal models following cobalt-60 gamma irradiation. *J Cancer Res Ther.* 2017, epub ahead of print.
- Hasanoglu A, Ara C, Ozen S, Kali K, Senol M, Ertas E. Efficacy of micronized flavonoid fraction in healing of clean and infected wounds. *Int J Angiol.* 2001;10(1):41-4.
- Heinke J, Patterson C, Moser M. Life is a pattern: vascular assembly within the embryo. *Front Biosci (Elite Ed).* 2012;4:2269-88.
- Honmore V, Kandhare A, Zanwar AA, Rojatkhar S, Bodhankar S, Natu A. *Artemisia pallens* alleviates acetaminophen induced toxicity via modulation of endogenous biomarkers. *Pharm Biol.* 2015;53:571-81.
- Hozzein WN, Badr G, Al Ghamdi AA, Sayed A, Al-Waili NS, Garraud O. Topical application of propolis enhances cutaneous wound healing by promoting TGF-beta/Smad-mediated collagen production in a streptozotocin-induced type I diabetic mouse model. *Cell Physiol Biochem.* 2015;37:940-54.
- Ibrahim SS. Protective effect of hesperidin, a citrus bioflavonoid, on diabetes-induced brain damage in rats. *J Appl Sci Res.* 2008;4(1):84.
- Jeansson M, Gawlik A, Anderson G, Li C, Kerjaschki D, Henkelman M, et al. Angiopoietin-1 is essential in mouse vasculature during development and in response to injury. *J Clin Invest.* 2011;121:2278-89.
- Jin YR, Han XH, Zhang YH, Lee JJ, Lim Y, Kim TJ, et al. Hesperetin, a bioflavonoid, inhibits rat aortic vascular smooth muscle cells proliferation by arresting cell cycle. *J Cell Biochem.* 2008;104(1):1-14.
- Kamble H, Kandhare AD, Bodhankar S, Mohan V, Thakurdesai P. Effect of low molecular weight galactomannans from fenugreek seeds on animal models of diabetes mellitus. *Biomed Aging Pathol.* 2013;3:145-51.
- Kandhare A, Raygude K, Ghosh P, Gosavi T, Bodhankar S. Patentability of animal models: India and the Globe. *Int J Pharm Biol Arc.* 2011;2:1024-32.
- Kandhare AD, Raygude KS, Ghosh P, Ghule AE, Bodhankar SL. Neuroprotective effect of naringin by modulation of endogenous biomarkers in streptozotocin induced painful diabetic neuropathy. *Fitoterapia.* 2012a;83:650-9.
- Kandhare AD, Raygude KS, Ghosh P, Ghule AE, Bodhankar SL. Therapeutic role of curcumin in prevention of biochemical and behavioral aberration induced by alcoholic neuropathy in laboratory animals. *Neurosci Lett.* 2012b;511:18-22.
- Kandhare AD, Raygude KS, Kumar VS, Rajmane AR, Visnagri A, Ghule AE, et al. Ameliorative effects quercetin against impaired motor nerve function, inflammatory mediators and apoptosis in neonatal streptozotocin-induced diabetic neuropathy in rats. *Biomed Aging Pathol.* 2012c;2:173-86.
- Kandhare AD, Ghosh P, Ghule AE, Bodhankar SL. Elucidation of molecular mechanism involved in neuroprotective effect of Coenzyme Q10 in alcohol-induced neuropathic pain. *Fund Clin Pharmacol.* 2013;27:603-22.
- Kandhare AD, Ghosh P, Bodhankar SL. Naringin, a flavanone glycoside, promotes angiogenesis and inhibits endothelial apoptosis through modulation of inflammatory and growth factor expression in diabetic foot ulcer in rats. *Chem Biol Interact.* 2014;219:101-12.
- Kandhare AD, Bodhankar SL, Mohan V, Thakurdesai PA. Effect of glycosides based standardized fenugreek seed extract in bleomycin-induced pulmonary fibrosis in rats: Decisive role of Bax, Nrf2, NF- κ B, Muc5ac, TNF- α and IL-1 β . *Chem Biol Interact.* 2015a;237:151-65.
- Kandhare AD, Mukherjee A, Pasalkar SD, Ghate SA, Bodhankar SL. Light Emitting Diodes (LED) irradiation treatment ameliorates hyperbilirubinemia in obstructive jaundice in laboratory animals. *Pharmacologia.* 2015b;7:371-80.
- Kandhare AD, Patil A, Guru A, Mukherjee A, Sarkar A, Sengupta A, et al. Ameliorative effect of ferulic acid against acetic acid induced ulcerative colitis: Role of HO-1 and Nrf2. *Pharmacologia.* 2015c;7:114-24.

- Kandhare AD, Bodhankar SL, Mohan V, Thakurdesai PA. Acute and repeated doses (28 days) oral toxicity study of glycosides based standardized fenugreek seed extract in laboratory mice. *Regul Toxicol Pharmacol*. 2015d;72:323-34.
- Kandhare AD, Alam J, Patil MV, Sinha A, Bodhankar SL. Wound healing potential of naringin ointment formulation via regulating the expression of inflammatory, apoptotic and growth mediators in experimental rats. *Pharm Biol*. 2016a;54:419-32.
- Kandhare AD, Mukherjee A, Ghosh P, Bodhankar SL. Efficacy of antioxidant in idiopathic pulmonary fibrosis: A systematic review and meta-analysis. *EXCLI J*. 2016b;15:636-51.
- Kandhare AD, Patil MV, Bodhankar SL. Ameliorative effect of alkaloidal fraction of leaves of *Alstonia scholaris* against acetic acid induced colitis via modulation of oxido-nitrosative and pro-inflammatory cytokines. *Pharmacologia*. 2016c;7:170-81.
- Kandhare AD, Mukherjee A, Bodhankar SL. Antioxidant for treatment of diabetic nephropathy: A systematic review and meta-analysis. *Chem Biol Interact*. 2017a;278:212-21.
- Kandhare AD, Mukherjee A, Bodhankar SL. effect of hesperidin in bleomycin-induced pulmonary fibrosis in rats: critical role of Nrf-2, TNF- α , and IL-1 β . *Value Health*. 2017b;20:A887-A8.
- Kandhare AD, Mukherjee AA, Bodhankar SL. Neuroprotective effect of *Azadirachta indica* standardized extract in partial sciatic nerve injury in rats: Evidence from anti-inflammatory, antioxidant and anti-apoptotic studies. *EXCLI J*. 2017c;16:546-65.
- Kaur G, Tirkey N, Chopra K. Beneficial effect of hesperidin on lipopolysaccharide-induced hepatotoxicity. *Toxicology*. 2006;226:152-60.
- Kawaguchi K, Mizuno T, Aida K, Uchino K. Hesperidin as an inhibitor of lipases from porcine pancreas and *Pseudomonas*. *Biosci Biotechnol Biochem*. 1997;61(1):102.
- Ketkar S, Rathore A, Kandhare A, Lohidasan S, Bodhankar S, Paradkar A, et al. Alleviating exercise-induced muscular stress using neat and processed bee pollen: oxidative markers, mitochondrial enzymes, and myostatin expression in rats. *Integr Med Res*. 2015;4:147-60.
- Koh GY. Orchestral actions of angiopoietin-1 in vascular regeneration. *Trends Mol Med*. 2013;19(1):31-9.
- Kumar VS, Rajmane AR, Adil M, Kandhare AD, Ghosh P, Bodhankar SL. Naringin ameliorates acetic acid induced colitis through modulation of endogenous oxido-nitrosative balance and DNA damage in rats. *J Biomed Res*. 2014;28:132-45.
- Lee N-K, Choi S-H, Park S-H, Park E-K, Kim D-H. Antiallergic activity of hesperidin is activated by intestinal microflora. *Pharmacology*. 2004;71:174-80.
- Leung P-C, Wong MW, Wong W-C. Limb salvage in extensive diabetic foot ulceration: an extended study using a herbal supplement. *Hong Kong Medical J*. 2008;14(1):29.
- Mohod SM, Kandhare AD, Bodhankar SL. Gastroprotective potential of Pentahydroxy flavone isolated from *Madhuca indica* JF Gmel. leaves against acetic acid-induced ulcer in rats: The role of oxido-inflammatory and prostaglandins markers. *J Ethnopharmacol*. 2016;182:150-9.
- Moulin V, Auger FA, Garrel D, Germain L. Role of wound healing myofibroblasts on re-epithelialization of human skin. *Burns*. 2000;26(1):3-12.
- Mukherjee A, Kandhare AD, Bodhankar SL. Effect of chrysin on gentamicin-induced nephrotoxicity in laboratory animals. *Pharmacologia*. 2015;7:296-307.
- Mukherjee AA, Kandhare AD, Rojatkar SR, Bodhankar SL. Ameliorative effects of *Artemisia pallens* in a murine model of ovalbumin-induced allergic asthma via modulation of biochemical perturbations. *Biomed Pharmacother*. 2017;94:880-9.
- Mustoe T. Understanding chronic wounds: a unifying hypothesis on their pathogenesis and implications for therapy. *Am J Surg*. 2004;187(5A):65S-70S.
- Nandakumar N, Jayaprakash R, Rengarajan T, Ramesh V, Balasubramanian MP. Hesperidin, a natural citrus flavonoglycoside, normalizes lipid peroxidation and membrane bound marker enzymes in 7, 12-Dimethylbenz (a) anthracene induced experimental breast cancer rats. *Biomed Prevent Nutr*. 2011;1:255-62.
- Nathan DM. Long-term complications of diabetes mellitus. *N Engl J Med*. 1993;328:1676-85.
- Navaratna D, Guo S, Arai K, Lo EH. Mechanisms and targets for angiogenic therapy after stroke. *Cell Adh Migr*. 2009;3:216-23.
- Nunan R, Harding KG, Martin P. Clinical challenges of chronic wounds: searching for an optimal animal model to recapitulate their complexity. *Dis Model Mech*. 2014;7:1205-13.

- Nwomeh BC, Liang HX, Cohen IK, Yager DR. MMP-8 is the predominant collagenase in healing wounds and nonhealing ulcers. *J Surg Res.* 1999;81:189-95.
- Pafumi I, Favia A, Gambarà G, Papacci F, Ziparo E, Palombi F, et al. Regulation of angiogenic functions by angiopoietins through calcium-dependent signaling pathways. *Biomed Res Int.* 2015;2015:965271.
- Panchatcharam M, Miriyala S, Gayathri VS, Suguna L. Curcumin improves wound healing by modulating collagen and decreasing reactive oxygen species. *Mol Cell Biochem.* 2006;290(1-2):87-96.
- Paocharoen V. The efficacy and side effects of oral *Centella asiatica* extract for wound healing promotion in diabetic wound patients. *J Med Assoc Thai.* 2010;93 (Suppl 7):S166-70.
- Patel DK, Prasad SK, Kumar R, Hemalatha S. An overview on antidiabetic medicinal plants having insulin mimetic property. *Asian Pac J Trop Biomed.* 2012;2: 320-30.
- Patil M, Kandhare A, Bhise S. Pharmacological evaluation of ameliorative effect of aqueous extract of *Cucumis sativus* L. fruit formulation on wound healing in Wistar rats. *Chronicles Young Scient.* 2011;2:207-13.
- Patil MVK, Kandhare AD, Bhise SD. Anti-arthritis and anti-inflammatory activity of *Xanthium strumarium* L. ethanolic extract in Freund's complete adjuvant induced arthritis. *Biomed Aging Pathol.* 2012a;2:6-15.
- Patil MVK, Kandhare AD, Bhise SD. Anti-inflammatory effect of *Daucus carota* root on experimental colitis in rats. *Int J Pharm Pharm Sci.* 2012b;4(1):337-43.
- Patil MVK, Kandhare AD, Bhise SD. Pharmacological evaluation of ethanolic extract of *Daucus carota* Linn root formulated cream on wound healing using excision and incision wound model. *Asian Pac J Trop Biomed.* 2012c;2:S646-S55.
- Patil MVK, Kandhare AD, Ghosh P, Bhise SD. Determination of role of GABA and nitric oxide in anticonvulsant activity of *Fragaria vesca* L. ethanolic extract in chemically induced epilepsy in laboratory animals. *Orient Pharm Exp Med.* 2012d;12:255-64.
- Perez Gutierrez R, Vargas SR. Evaluation of the wound healing properties of *Acalypha langianain* diabetic rats. *Fitoterapia.* 2006;77:286-9.
- Phillips GD, Whitehead RA, Knighton DR. Initiation and pattern of angiogenesis in wound healing in the rat. *Am J Anat.* 1991;192:257-62.
- Pires Das Neves RN, Carvalho F, Carvalho M, Fernandes E, Soares E, Bastos MDL, et al. Protective activity of hesperidin and lipoic acid against sodium arsenite acute toxicity in mice. *Toxicol Pathol.* 2004;32: 527-35.
- Rafehi H, El-Osta A, Karagiannis TC. Genetic and epigenetic events in diabetic wound healing. *Int Wound J.* 2011;8(1):12-21.
- Raghow R. The role of extracellular matrix in postinflammatory wound healing and fibrosis. *FASEB J.* 1994;8:823-31.
- Raygude KS, Kandhare AD, Ghosh P, Ghule AE, Bodhankar SL. Evaluation of ameliorative effect of quercetin in experimental model of alcoholic neuropathy in rats. *Inflammopharmacology.* 2012;20:331-41.
- Reiser KM. Nonenzymatic glycation of collagen in aging and diabetes. *Proc Soc Exp Biol Med.* 1991;196(1): 17-29.
- Ricard-Blum S, Ruggiero F. The collagen superfamily: from the extracellular matrix to the cell membrane. *Pathol Biol (Paris).* 2005;53:430-42.
- Shah JK, Patel N. Effect of hesperidin on renal complication in experimentally induced renal damage in diabetic sprague dawley rats. *J Ecobiotechnol.* 2010;2(2).
- Shi X, Liao S, Mi H, Guo C, Qi D, Li F, et al. Hesperidin prevents retinal and plasma abnormalities in streptozotocin-induced diabetic rats. *Molecules.* 2012;17: 12868-81.
- Shivakumar V, Kandhare AD, Rajmane AR, Adil M, Ghosh P, Badgujar LB, et al. Estimation of the long-term cardiovascular events using ukpds risk engine in metabolic syndrome patients. *Indian J Pharm Sci.* 2014;76:174-8.
- Shukla A, Rasik AM, Patnaik GK. Depletion of reduced glutathione, ascorbic acid, vitamin E and antioxidant defence enzymes in a healing cutaneous wound. *Free Radic Res.* 1997;26:93-101.
- Sidhu GS, Mani H, Gaddipati JP, Singh AK, Seth P, Banaudha KK, et al. Curcumin enhances wound healing in streptozotocin induced diabetic rats and genetically diabetic mice. *Wound Repair Regen.* 1999;7: 362-74.
- Struckmann JR, Nicolaidis AN. Flavonoids a review of the pharmacology and therapeutic efficacy of Daflon 500 mg in patients with chronic venous insufficiency and related disorders. *Angiology.* 1994;45:419-28.
- Suarez S, Ballmer-Hofer K. VEGF transiently disrupts gap junctional communication in endothelial cells. *J Cell Sci.* 2001;114:1229-35.

- Suh DD, Schwartz IP, Canning DA, Snyder HM, Zderic SA, Kirsch AJ. Comparison of dermal and epithelial approaches to laser tissue soldering for skin flap closure. *Lasers Surg Med.* 1998;22:268-74.
- Sumitra M, Manikandan P, Suguna L. Efficacy of *Butea monosperma* on dermal wound healing in rats. *Int J Biochem Cell Biol.* 2005;37:566-73.
- Tambewagh UU, Kandhare AD, Honmore VS, Kadam PP, Khedkar VM, Bodhankar SL, et al. Anti-inflammatory and antioxidant potential of Guaianolide isolated from *Cyathocline purpurea*: Role of COX-2 inhibition. *Int Immunopharmacol.* 2017;52:110-8.
- Teoh SL, Latiff AA, Das S. The effect of topical extract of *Momordica charantia* (bitter gourd) on wound healing in nondiabetic rats and in rats with diabetes induced by streptozotocin. *Clin Exp Dermatol.* 2009;34:815-22.
- Vijay SK, Mishra M, Kumar H, Tripathi K. Effect of pioglitazone and rosiglitazone on mediators of endothelial dysfunction, markers of angiogenesis and inflammatory cytokines in type-2 diabetes. *Acta Diabetol.* 2009;46(1):27-33.
- Visconti RP, Richardson CD, Sato TN. Orchestration of angiogenesis and arteriovenous contribution by angiopoietins and vascular endothelial growth factor (VEGF). *Proc Natl Acad Sci U S A.* 2002;99:8219-24.
- Visnagri A, Kandhare AD, Shiva Kumar V, Rajmane AR, Mohammad A, Ghosh P, et al. Elucidation of ameliorative effect of Co-enzyme Q10 in streptozotocin-induced diabetic neuropathic perturbation by modulation of electrophysiological, biochemical and behavioral markers. *Biomed Aging Pathol.* 2012;2:157-72.
- Visnagri A, Kandhare AD, Ghosh P, Bodhankar SL. Endothelin receptor blocker bosentan inhibits hypertensive cardiac fibrosis in pressure overload-induced cardiac hypertrophy in rats. *Cardiovasc Endocrinol.* 2013;2(4):85-97.
- Visnagri A, Kandhare AD, Chakravarty S, Ghosh P, Bodhankar SL. Hesperidin, a flavanoglycone attenuates experimental diabetic neuropathy via modulation of cellular and biochemical marker to improve nerve functions. *Pharm Biol.* 2014;52:814-28.
- Wall SJ, Sampson MJ, Levell N, Murphy G. Elevated matrix metalloproteinase-2 and -3 production from human diabetic dermal fibroblasts. *Br J Dermatol.* 2003;149(1):13-6.
- World Health Organization. Global report on diabetes. Geneva: WHO, 2016.
- Wu FR, Jiang L, He XL, Zhu PL, Li J. Effect of hesperidin on TGF-beta1/Smad signaling pathway in HSC. *Zhongguo Zhong Yao Za Zhi.* 2015;40:2639-43.
- Xu F, Zhang C, Graves DT. Abnormal cell responses and role of TNF-alpha in impaired diabetic wound healing. *Biomed Res Int.* 2013;2013:754802.
-